

Teeth Wearing Thin?

Customized treatment plan adds strength, aesthetic appeal

The four-wheel cart was loaded down with boxes of ammunition and dozens of gallons of fuel, and Robert Lovell was sitting on top of it all that day when a sniper fired into the US military base where Robert was stationed in Vietnam.

beat cancer, but the radiation treatments that helped him win that battle left him with a dental issue.

“My teeth were getting very thin from all the radiation, and I knew it was just a matter of time before they would start breaking,” Robert relates. “I didn’t want to have to deal with all that, too, so I went to see my guys at DeLand Implant Dentistry.”



DELAND IMPLANT DENTISTRY
RAJIV PATEL, BDS, MDS
JAYRAJ J. PATEL, DMD

Considering the payload, Robert considers himself rather lucky the shot hit him in the left shoulder. Had it hit the driver or ricocheted and sparked a fire or explosion, there’s no telling what kind of disaster might have unfolded.

“Every Purple Heart has a story, and that’s mine,” Robert says of the medal awarded to members of the US military wounded or killed in action. “We were on our way to refuel a Cobra gunship (helicopter) when the sniper came through.

“You grow from a boy to a man in a split second when something like that happens to you. I thought that any career I might have (following the military) was going to be very short-lived.”

Closing the Gap

DeLand Implant Dentistry is the practice of Rajiv Patel, BDS, MDS, and his nephew, Jayraj J. Patel, DMD. Robert has been a patient there for about five years. This time, he was treated by Dr. Jayraj Patel, who agreed there was reason for concern.

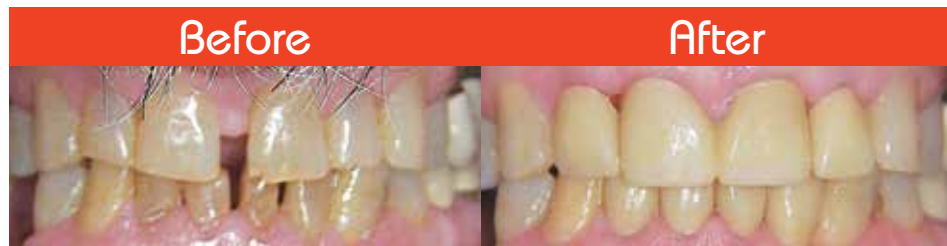
“Radiation treatments can take a toll on the body and also affect the teeth. Robert was concerned he might have some serious issues with those teeth breaking on him down the road, so he asked me what we could do to prevent that,” Dr. Patel reports.

“He also had some natural gaps between his two front teeth in the upper arch and his front teeth in the lower arch.



“My new crowns look fabulous and feel great.”

- David



Thankfully, that wasn’t the case. Robert’s shoulder injury didn’t even shorten his time in Vietnam. A member of the 229th Assault Helicopter Battalion, he spent a year there, eventually leaving December 23, 1972.

He later became a maintenance technician.

“I did it all – heat, air conditioning, refrigeration, you name it,” says Robert, 71. “I was cross-trained in five different fields and worked 40-something years with different organizations despite always having some issues with that shoulder.”

Those aren’t the only issues Robert has dealt with over the years. He also

I told him that by placing crowns and connecting a couple of them, we could not only strengthen his teeth but fill in those gaps as well.”

Seeing an opportunity to strengthen his teeth and enhance his smile, Robert agreed to the treatment plan proposed by Dr. Patel, who began his work by taking standard impressions of Robert’s teeth. From those impressions, he produced a diagnostic wax-up of the finished product.

“The wax-up allows the patient to actually see what it is we’re proposing,” Dr. Patel explains. “They can see the size and shape of the crowns and what their smile will look like in the end as opposed to guessing.”

Robert’s plan called for Dr. Patel to place new crowns on each of the front four teeth in Robert’s top arch and each of the front four teeth in his bottom arch. Preparing those teeth for crowns and placing temporary crowns was the second phase of the project.

“The temporary crowns are made in our office from the wax-up,” Dr. Patel explains. “The temporary crowns are very similar to the final crowns, and

the patient wears those for a week or so while the permanent crowns are being made at the lab.

“During that time, the patient can decide what they like or maybe don’t like about the crowns and, if needed, we make any changes in shape, size or bite in the design of the final crowns and then fabricate the final crowns.”

Depending on the tooth being crowned and the color desired, a variety of materials, including lithium disilicate and zirconia, can be used to create new crowns.

In all cases, though, the new crowns are monolithic, meaning they are formed from a single block of zirconia. That creates several natural advantages over older crowns made of porcelain fused to metal. For starters, monolithic crowns are stronger. They are also more aesthetically pleasing, in part because there is no metal collar at the top.

“A Marvelous Job”

The thinning of his teeth did not cause Robert any pain or force him to alter his eating habits. He was fearful, though, those problems might develop if he wasn’t proactive.

Now, Robert is smiling and eating with more confidence than ever.

“Dr. Patel did a marvelous job,” Robert raves. “My new crowns look fabulous and feel great. There are no issues with them at all, and I can eat without any worries that they’re going to break.

“Once again, my experience with DeLand Implant Dentistry was a pleasant one. I’ve never had a bad experience there, which is why I wholeheartedly recommend them.

“Everyone is so nice and so professional, and it all starts with (office coordinator) Cathy (Johnson). She’s such a wonderful person, and she’s always up to date on everything. It’s the same with Dr. Patel and the rest of the staff. They’re as good as it gets.”

© FHCN article by Roy Cummings. Photo by Jordan Pysz. mkb

Call Today!

Rajiv Patel, BDS, MDS, and Jayraj J. Patel, DMD, are known for their exceptional, caring attitude toward their patients and work. They are committed to delivering the most advanced, personalized dental care while offering patients a uniquely satisfying experience. Along with the staff of DeLand Implant Dentistry, they welcome new patients and any questions concerning their range of services, including cleanings and preventive care, sedation methods, and cosmetic, restorative, prosthetic and implant dentistry. For an appointment, call or visit the office in DeLand in the Spring Oaks Professional Center:

150 McGregor Rd.
(386) 738-2006

Rajiv Patel, BDS, MDS, has practiced general dentistry in DeLand for more than 30 years. He is board-certified in implant dentistry through his designation as a diplomate of the American Board of Oral Implantology/Implant Dentistry. Additionally, he is a fellow of the American Academy of Implant Dentistry and International Congress of Oral Implantologists. He is one of the select few general dentists certified to administer IV sedation in a dental office. He is a member of the Florida Dental Association, American Dental Association and Florida Dental Society of Anesthesiology.



Jayraj J. Patel, DMD, has been practicing general dentistry since graduating from the University of Florida College of Dentistry. His goal is to deliver comprehensive, compassionate care to his patients in a caring, comfortable and professional environment. He strives to provide advanced, personalized and complete care to each patient using the latest technologies and treatment modalities with an aim to build a long-term relationship based on trust, respect and friendship. Dr. Patel has extensive training in dental implant therapy through comprehensive courses such as the AAID Maxi Course from Augusta University Dental College of Georgia and the Comprehensive Implant Continuum from Implant Educators. He is a fellow of the International Congress of Oral Implantologists, an associate fellow of the American Academy of Implant Dentistry and a fellow of the Academy of General Dentistry. He is pursuing certification from the American Board of Oral Implantology/Implant Dentistry.



For detailed information about DeLand Implant Dentistry, visit delandimplants.com